

REVIEW ARTICLE

Dan L. Longo, M.D., *Editor*

Acute Spinal Cord Compression

Alexander E. Ropper, M.D., and Allan H. Ropper, M.D.

From the Department of Neurosurgery, Baylor College of Medicine, Houston (A.E.R.).

This article was updated on April 6, 2017, at NEJM.org.

N Engl J Med 2017;376:1358-69.
DOI: 10.1056/NEJMra1516539

Copyright © 2017 Massachusetts Medical Society.

ACUTE COMPRESSION OF THE SPINAL CORD IS A DEVASTATING BUT TREATABLE disorder. Diseases that cause acute spinal cord compression constitute a special category because they originate in the spinal column and narrow the spinal canal. This review addresses the disorders that account for most instances of acute spinal cord compression: trauma, tumor, epidural abscess, and epidural hematoma. The pathophysiological features and management of these disorders are similar to those of other acute and serious spinal conditions.

The medical context of spinal cord compression determines the diagnosis and directs treatment. Traumatic cord compression is often self-evident. Cord compression in patients with cancer is generally due to metastasis to the spinal column, cord compression in patients with sepsis or in patients who are intravenous drug users suggests epidural abscess, and cord compression associated with anticoagulant therapy, antiplatelet therapy, or coagulopathy is likely to be caused by epidural hematoma.

The disorders discussed here also damage vertebrae, intervertebral disks, ligaments, and facet joints, leading to instability of the spinal column. Stability is defined by the retention of normal spinal alignment under physiologic conditions (loads) such as standing, walking, bending, or lifting. This biomechanical concept is essential to an understanding of cord compression, because spinal instability (see the Glossary) permits spondylolisthesis, which narrows the spinal canal. Instability that poses a risk of cord damage generally requires surgical fixation of the spine, and bony fusion of adjacent vertebrae (spinal fusion) may be necessary for durable stabilization.

CLINICAL FEATURES OF ACUTE SPINAL CORD COMPRESSION

The cardinal features of acute spinal cord compression are relatively symmetric paralysis of the limbs, urinary retention or incontinence, and a circumferential boundary below which there is loss of sensation, referred to as the “sensory level” (see the interactive graphic, available with the full text of this article at NEJM.org). Hyperreflexia and Babinski signs, which are characteristic of intrinsic diseases of the spinal cord, may not be evident in cases of acute and severe cord compression, particularly if the cause is trauma. The limbs may instead be flaccid and areflexic, accompanied by systemic hypotension — a combination of findings that constitutes the syndrome of spinal shock. Localized back or neck pain is an additional characteristic of most acute types of cord compression. Variations and partial presentations of the typical syndromes are common (Table 1). The spinal cord ends near the L1–L2 level, where it transitions to spinal roots that make up the cauda equina. Acute compression of the cauda equina by lesions in the lumbar spine causes flaccid paraparesis and early incontinence, findings that are similar to those in patients with the syndrome of spinal shock. Two frequent deficiencies in performing the physical examination are failure to seek a sensory level above the clavicles, a finding that would indicate cervical cord compression, and omis-



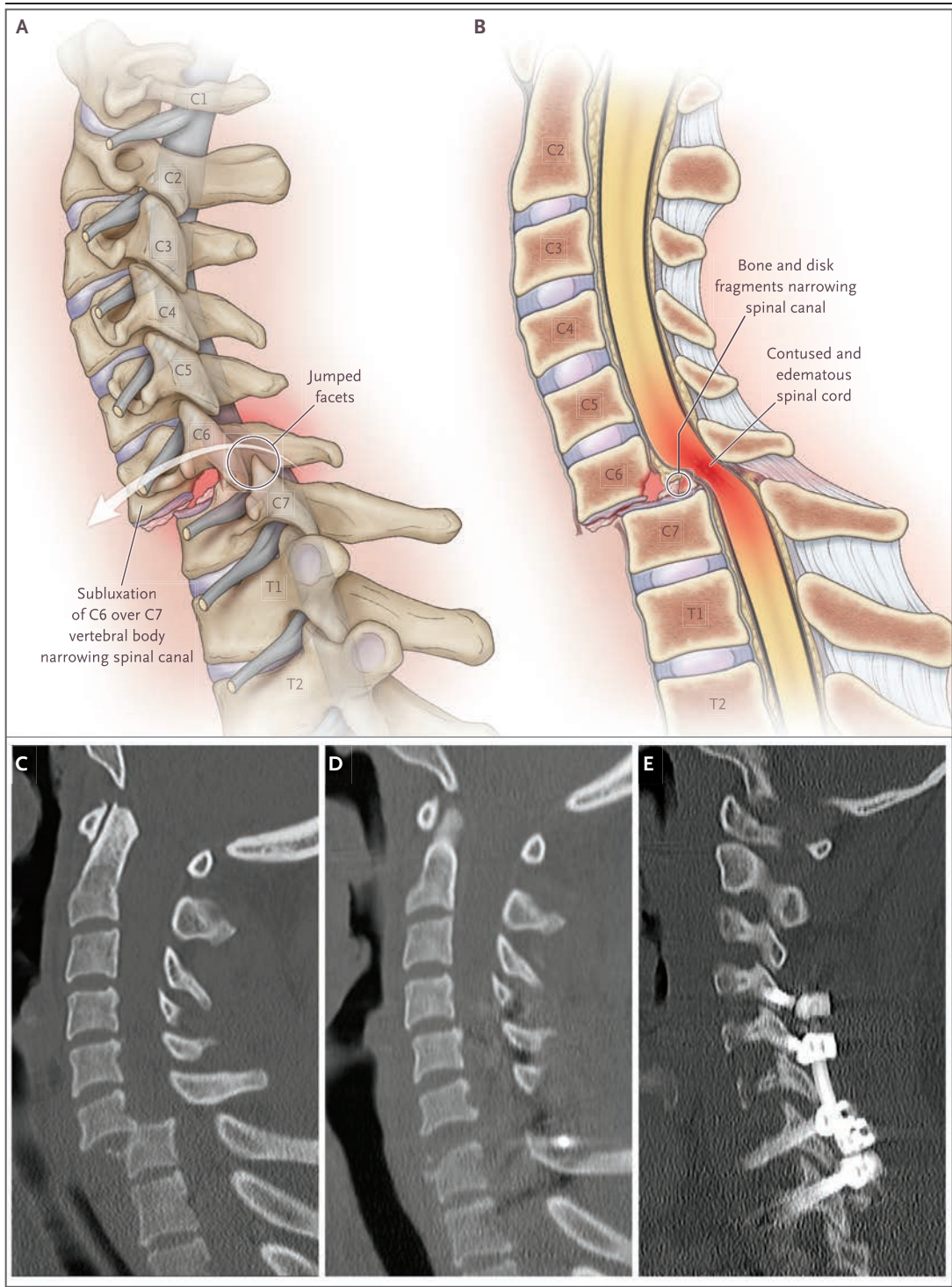
An interactive graphic is available at NEJM.org

Glossary

<p>Conus medullaris: Caudal end of the spinal cord, containing the lumbar and sacral portions of the spinal cord, usually located at L1–L2.</p> <p>Pseudoarthrosis: Nonunion of adjacent vertebral bodies after spinal fusion.</p> <p>Reduction: Restoration of normal spinal alignment.</p> <p>Sensory level: A circumferential line on the trunk below which sensation is absent or diminished.</p> <p>Spinal deformity: Abnormal alignment of the vertebral column.</p> <p>Spinal fixation: Stabilization of the spine, usually used in reference to operative stabilization with instrumentation.</p> <p>Spinal fusion: Bony union of adjacent vertebral levels.</p> <p>Spinal instability: Dynamic displacement of adjacent vertebrae under physiologic loads.</p> <p>Spondylolisthesis: Subluxation of a vertebral segment on an adjacent one.</p>

Table 1. Clinical Syndromes of Acute Spinal Cord Compression.

<p>Complete transverse myelopathy (lesion affecting both sides and anterior and posterior spinal cord at one or more segments)</p> <ul style="list-style-type: none"> Bilateral paralysis below lowest affected segment of spinal cord Loss or reduction of all sensation below affected level of spinal cord (sensory level) Sphincter dysfunction with urinary or bowel urgency, retention, or incontinence Segmental loss of reflexes at affected level Hyperreflexia and Babinski signs <p>Spinal shock (acute destruction of spinal cord at one or more cervical or upper thoracic segments)</p> <ul style="list-style-type: none"> Paralysis of limbs below the affected segment of the spinal cord Hypotonia and areflexia of limbs below the level of the lesion No Babinski signs Loss of sphincter function Reduced autonomic function below affected level Systemic hypotension <p>Central cord syndrome (predominant gray-matter damage, typically involving cervical spine, from trauma)</p> <ul style="list-style-type: none"> Weakness and reflex loss in arms; less severe weakness or no weakness in legs Reduced pain and thermal sense in arms, typically with hyperesthesia, sparing sensation of vibration and proprioception in arms and legs Variable hyperreflexia in legs <p>Hemicord (Brown–Séquard) syndrome</p> <ul style="list-style-type: none"> Paralysis, hyperreflexia, and reduced sensation of vibration on one side of body Babinski sign on paralyzed side Loss of pain and thermal sense on opposite side <p>Conus medullaris syndrome (cord compression at the level of L1–L2 vertebral bodies)</p> <ul style="list-style-type: none"> Weakness of feet and legs Variable reflexes in legs Early loss of sphincter function Loss of sensation at sacral and lower lumbar (perineal) dermatomes; sensory level at or below waist Variable Babinski signs <p>Cauda equina syndrome (compression between L2 and S1 vertebral bodies)</p> <ul style="list-style-type: none"> Sciatic or other radicular pain Areflexic weakness of feet and legs, depending on level of compression Sphincter dysfunction Reduced sensation from saddle region and legs up to groin
--



sion of spinal percussion, a maneuver that can reveal metastatic disease or fracture. These examination features are shown in the interactive graphic. The eminent neurosurgeon Walter Dandy,

who introduced imaging for spinal cord compression in the 1920s, stated that “a correct diagnosis and localization of spinal tumors can be made in over 90 percent of cases by painstaking

Figure 1 (facing page). Acute Cord Compression Due to Trauma to the Cervical Spine.

A lateral view of the cervical spine (Panel A) shows traumatic spondylolisthesis, in which the facets of the C6 vertebra have “jumped” over those of C7. Bone fragments from fracture of the vertebral bodies have been impelled into the spinal canal, and the C6–C7 disk has ruptured through the annulus. The misalignment and the material within the spinal canal cause acute compression of the spinal cord. A midsagittal view of the cervical spine (Panel B) shows spinal cord edema and hemorrhage extending caudally and rostrally from the level of spondylolisthesis. The anterior and posterior longitudinal ligaments and the ligamentum flavum are torn, allowing displacement of the vertebral bodies. Bone and disk material exacerbate the narrowing of the spinal canal. A midsagittal CT image from a patient who had been in a high-speed motor vehicle accident (Panel C) shows severe spondylolisthesis at C6–C7, with narrowing of the spinal canal and worsening cord compression. A postoperative midsagittal CT image (Panel D) shows reduction of the spondylolisthesis shown in Panel C, realignment of the spine, and decompression of the spinal canal. A parasagittal CT image (Panel E) shows spinal fixation, from C4 through T1, with the use of posterior screws and rods, supplemented with a bone graft to create arthrodesis. This spinal reconstruction can also be performed anteriorly.

neurological examination.”¹ Although this observation is not as salient in the modern era of magnetic resonance imaging (MRI), a careful neurologic examination remains an essential part of the evaluation for spinal cord compression.

TRAUMATIC SPINAL CORD
COMPRESSION

Acute traumatic spinal cord compression results from combinations of fractured and retropulsed bone fragments, disk herniation, and subluxation of the vertebral bodies (Fig. 1A, 1B, and 1C). It is possible for spinal cord damage to occur without fracture — for example, in the case of minor trauma superimposed on chronic degenerative spondylosis that has narrowed the spinal canal. In patients with severe trauma or those taking anticoagulant or antiplatelet medications, spinal epidural hematoma may worsen cord compression.

As many as 20% of spinal injuries affect more than one level,² but the cervical spine is especially vulnerable to displacement because it lacks the support of the rib cage and its facet joints are smaller and more axially oriented than the

joints of the thoracolumbar spine.³ In addition, since the cranium constitutes a load on the fulcrum of the neck, head trauma can cause cervical spinal damage. Injury of the cervical segments generates the most serious neurologic disabilities: tetraplegia and respiratory failure. Most of the discussion that follows pertains to the cervical spine, but the basic principles also apply to the thoracic and lumbar spines.

ASSESSMENT

The neurologic effects of traumatic spinal cord injury are classified on the basis of anatomical level and the severity of the neurologic deficit. The level is determined by the lowest cord segment with normal motor and sensory function. Severity may be graded with the use of a number of systems, but the most common is the American Spinal Injury Association Impairment Scale (AIS), which grades impairment on a five-point scale from A (complete loss of neurologic function below the affected level) to E (normal function) (Table 2).⁴ Even slight preservation of sensation (AIS grade B), which most commonly occurs in the perineum, is associated with a better neurologic outcome than AIS grade A.

Guidelines for the evaluation of spinal trauma in patients with normal neurologic examinations focus on establishing spinal stability so that the spine will not be subject to subluxation and cord compression when the patient is mobile. Instability is unlikely in the absence of cervical pain or tenderness and with the full range of motion of the neck preserved. These findings make imaging and immobilization of the neck generally unnecessary, assuming that the patient is awake, is not intoxicated, and has no additional injuries or other conditions that might interfere with the ability to report neck pain.^{5,6}

In patients with neurologic abnormalities indicative of traumatic cord compression, computed tomography (CT) is preferred as the initial imaging study because of its sensitivity for detecting fracture and vertebral subluxation (Table 3 and Fig. 1C).⁷ MRI is a useful complementary study for revealing ligamentous damage, disk herniation, and edema or hemorrhage in the spinal cord. A problem commonly arises in patients who are obtunded or comatose and therefore unable to cooperate for a neurologic examination or dependably report pain. In these circumstances,

Table 2. ASIA Impairment Scale for Traumatic Spinal Cord Injury.*

Grade	Impairment
A	Complete: no sensory or motor function is preserved in segments S4–S5.
B	Sensory incomplete: sensory but not motor function is preserved below the neurologic level of injury and includes the S4–S5 segments; no motor function is preserved more than three levels below the motor level on either side of the body.
C	Motor incomplete: motor function is preserved at the most caudal sacral segments for voluntary anal contraction, or sensory function is preserved at the most caudal sacral segments (S4–S5), with some sparing of motor function more than three levels below the motor level on either side of the body.
D	Motor incomplete: motor function is incomplete as defined above, with muscle power ≥ 3 for at least half the key muscle functions below the neurologic level of injury.†
E	Normal: sensory and motor function are normal.

* Data are adapted from the American Spinal Injury Association (ASIA).⁴

† Muscle power is graded on a scale from 0 (no muscle contraction) to 5 (normal power).

MRI can be used to provide evidence that the disks and ligaments are undamaged and that, in most cases, a cervical collar or other immobilization device may be removed. In resource-limited areas, radiographic imaging with anteroposterior, lateral, and odontoid views of the cervical spine may suffice to detect major fractures and misalignment.

Another supplemental study is dynamic, lateral radiographic imaging of the cervical spine during flexion and extension. The absence of displacement of the vertebral bodies with these maneuvers establishes that the spine is stable, but to perform this study safely, the patient must be alert and able to restrict movement if it causes pain or neurologic symptoms.

TREATMENT

Most treatment guidelines for acute traumatic spinal cord injury⁸ are not based on randomized trials, but certain aspects should be underscored. The use of high-dose intravenous methylprednisolone has been controversial because randomized trials with positive results^{9,10} were followed by reanalysis and several trials with negative results.¹¹ For this reason, most institutions have abandoned the use of high-dose glucocorticoids for spinal trauma.¹² Retrospective case series and several small, prospective case series have suggested that systemic hypotension in the first few hours after injury is associated with a poor neurologic outcome, a finding that is also characteristic of severe head trauma. The putative mechanism of systemic hypotension is a loss of vascular autoregulation. Clinical guidelines in-

clude rapid reversal of hypotension and intravenous administration of vasopressors, if required, to maintain a mean arterial blood pressure of 85 to 90 mm Hg for a week after the injury.¹³

SURGERY

Traumatic cord compression is treated by removal of bone and disk fragments from the spinal canal and correction of misalignment (i.e., reduction). In a prospective case series, the neurologic outcome at 6 months was better if surgical decompression had been performed within 24 hours after the injury than if surgery had been delayed,¹⁴ but evidence for the best timing is limited. Surgically stabilizing the spine at the time of decompression allows for early mobilization and rehabilitation and putatively reduces the risks of pneumonia and venous thrombosis. Stabilization is achieved by means of internal fixation with screws placed in the vertebrae or posterior bony structures, which are linked with rods or plates (Fig. 1D and 1E). Fusion of vertebral segments may be necessary for long-term stability and is effected by decorticating the surfaces of adjacent bones and applying an autologous or cadaveric bone graft or synthetic material (see the interactive graphic). Bone healing over a period of several months creates an arthrodesis between adjacent vertebral bodies. The combined decompression, fixation, and fusion procedure is subject to infrequent but serious complications of infection, hardware failure, pseudoarthrosis, and delayed degenerative changes at adjacent spinal levels. Traction may restore spinal alignment, and external fixation with a halo or brace may

Table 3. Main Clinical and Imaging Characteristics of Acute Spinal Cord Compression and Treatment Options.*

Variable	Traumatic Cord Compression	Neoplastic Cord Compression	Spinal Epidural Abscess	Spinal Epidural Hematoma
Characteristics				
Temporal evolution	Sudden (at time of injury)	Days or longer	Hours, days, or longer	Sudden
Predisposing factors	High-velocity trauma, narrowed spinal canal (congenital or degenerative)	Systemic cancer with bony metastases, myeloma, lymphoma	Diabetes, cancer, bacteremia, intravenous drug use, recent spinal surgery	Treatment with anticoagulant or anti-platelet agents, coagulopathy, spinal trauma
Typical symptoms and signs	Paraplegia or tetraplegia, sensory level, central cord syndrome, focal spinal pain	Local back pain, nocturnal back pain, radicular pain, paraparesis, sensory level, sphincter dysfunction	Severe midline back pain, fever, paraparesis	Local or regional back pain, paraparesis
Laboratory abnormalities	Resulting from trauma to other organs	Manifestations of metastatic cancer and bony infiltration	Leukocytosis, elevated ESR and hsCRP, positive blood cultures	Elevated INR, prolonged PTT, platelet dysfunction, or thrombocytopenia
CT findings	Fracture of elements of spinal column, subluxation of vertebral bodies	Bony infiltration by neoplasm, multiple sites of metastases, pathologic compression fracture	Osteomyelitis or diskitis, which can cross disk space between adjacent vertebral bodies; paraspinous soft-tissue fluid collections	Hematoma may be evident; spinal fracture may be seen if hematoma is traumatic
MRI findings	High STIR signal in ligaments, cord edema and hemorrhage, subluxation	Enhancing tumor extending into spinal canal from spinal column, with disk space spared; homogeneous signal changes in vertebral body; tumor mass may be evident without gadolinium	Enhancing infectious collection, decreased signal on T ₁ -weighted images and increased signal on T ₂ -weighted images, and high STIR signal; osteomyelitis, diskitis, or enhancing paraspinous collection may be seen	Clot that is isointense on T ₁ -weighted images and hyperintense on T ₂ -weighted images, becoming hyperintense on T ₁ -weighted images after 24–36 hr
Treatment options				
Medical treatment	Maintenance of mean arterial blood pressure at 85 to 90 mm Hg, bladder catheterization	High-dose glucocorticoids, radiotherapy or radiosurgery	Antibiotics, including those for <i>Staphylococcus aureus</i> , until culture results guide change	Reversal of anticoagulation or platelet dysfunction
Surgical treatment	Decompression of spinal cord, restoration of alignment, internal fixation and fusion	Circumferential removal of tumor, decompression of spinal cord, internal fixation and fusion	Surgical evacuation with irrigation, biopsy, and culture	Surgical evacuation

* ESR denotes erythrocyte sedimentation rate, hsCRP high-sensitivity C-reactive protein, INR international normalized ratio, PTT partial-thromboplastin time, and STIR short T₁-weighted inversion-recovery sequence on MRI.

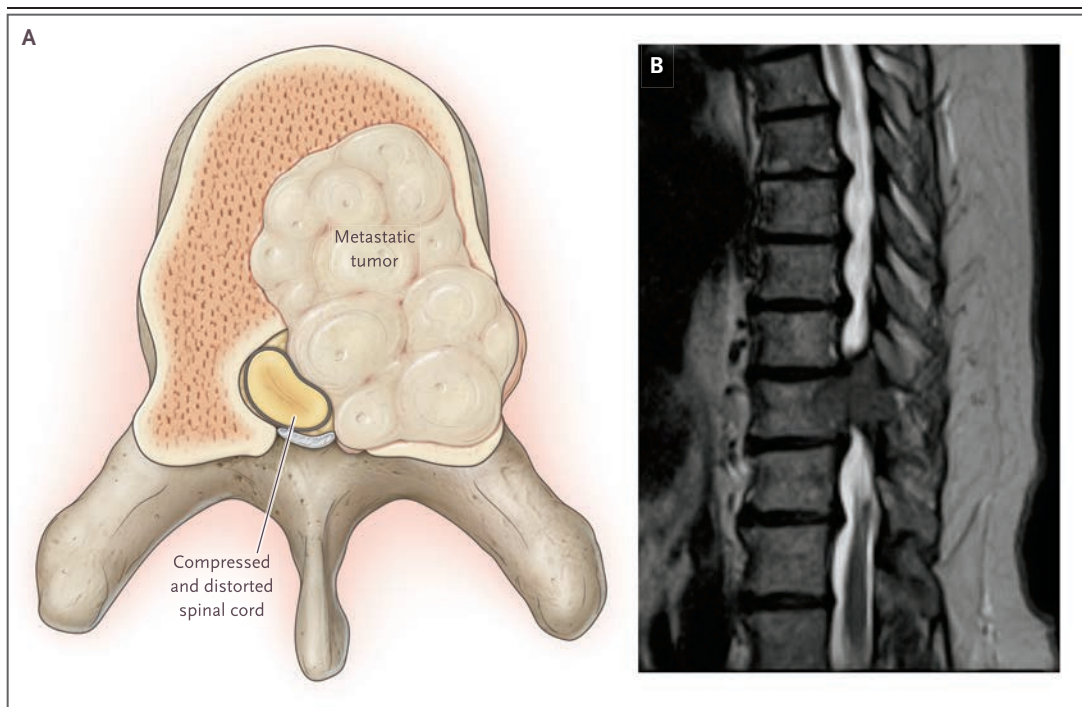


Figure 2. Acute Cord Compression Due to Metastatic Cancer to a Vertebral Body.

An axial view (Panel A) shows a thoracic vertebral body infiltrated by a metastatic tumor. The tumor extends from the bone and narrows the spinal canal, causing distortion and compression of the spinal cord (see the interactive graphic, available at NEJM.org). A parasagittal view of a T₂-weighted MRI (Panel B) shows metastasis of renal cancer to the T10 vertebral body and pedicle, causing severe narrowing of the spinal canal.

maintain alignment, but these are not usually durable treatments for spinal cord compression.¹⁵

NEOPLASTIC EPIDURAL SPINAL CORD COMPRESSION

Spinal metastases are common in cancer, but they cause spinal cord compression only when they extend from the bone into the epidural space (Fig. 2A). Aching back pain and tenderness on percussion over the affected site are typical and may precede neurologic features by several weeks. Pain may be worse when the patient is supine and causes awakening from sleep. The spinal cord syndrome evolves over a period of hours or days and includes hyperreflexia and Babinski signs but is infrequently characterized by sphincter dysfunction alone. With bony destruction and pathologic vertebral compression fracture, the spinal column becomes unstable, leading to more severe back pain.

A review of this subject in the *Journal* a quarter-century ago emphasized that breast, prostate,

and lung cancers were the most frequent causes of metastasis to the vertebral column,¹⁶ but non-Hodgkin's lymphoma, renal-cell cancer, and myeloma are also common causes.¹⁷ In some instances, the primary tumor cannot be identified. In children, sarcoma, neuroblastoma, and lymphoma have been reported as the most frequent causes of spinal cord compression.¹⁸ The compression occurs in the thoracic, lumbar, and cervical segments in 60%, 25%, and 15% of cases, respectively,^{19,20} but imaging of the entire spine reveals multiple levels of compression in up to a third of cases.^{21,22} Survival in patients with multiple spinal metastases and cord compression is generally less than 6 months, but a retained ability to walk before treatment is associated with longer survival.^{23,24}

ASSESSMENT

Compression of the spinal cord by epidural tumor is detected by imaging, foremost MRI, preferably with the administration of gadolinium (Table 3 and Fig. 2B). MRI has been reported to be 100%

sensitive in detecting spinal cord compression, with the exception of compression in some ambulatory patients with minor motor deficits.^{25,26} Ideally, images of the entire spine should be obtained to ensure that additional lesions are not overlooked. When it is not possible to perform extensive imaging, the region corresponding to a sensory level or radiculopathy should be chosen. Tumor can be detected in many cases without the use of gadolinium, so MRI should not be withheld if the patient has a risk factor, such as allergy, for administration of the agent. CT myelography is an alternative in patients who cannot undergo MRI. CT without myelography and radiography show bony infiltration or vertebral collapse from tumor but are not sensitive for detecting cord compression.

TREATMENT

Treatment of malignant spinal cord compression by radiotherapy and surgical decompression is partly palliative, but relief of paraplegia and reduction of pain are possible for considerable periods. Vertebral infiltration with tumor that does not compress the cord can be managed with radiation if the spinal column is stable. Both surgical and radiation treatment are supplemented by glucocorticoids. A delay in treatment may be associated with loss of neurologic function.²⁷

Glucocorticoids

Glucocorticoids reduce neurologic impairment and spinal pain, but the most effective doses have not been established. An initial dose of 100 mg of dexamethasone has been used, but a small trial indicates that lower doses are probably equally effective.²⁸ For example, 10 mg administered intravenously, followed by an oral dose of 4 mg every 6 hours and decreasing amounts administered orally over subsequent weeks, is a typical regimen.²⁹ These doses have well-known risks, but they are appropriate because they mitigate cord edema and reduce pain and weakness.

Radiotherapy

Definitive treatment is guided by the extent of symptomatic cord compression, by the mechanical stability of the spine, and partly by the responsiveness of the tumor to radiation. When weakness and sensory changes are minimal and radiation can be delivered expeditiously, it may

be used to treat spinal cord compression, particularly for compression caused by hematologic tumors. The radioresponsiveness of different types of cancer has been established by consensus. Lymphoma, myeloma, and seminoma are regarded as highly responsive and are treated with radiotherapy almost independently of the degree of cord compression. Breast, prostate, and ovarian tumors are associated with varied but intermediate responses to radiotherapy and are considered for surgical resection, although they may be treated with radiotherapy. Non-small-cell lung cancer and renal, thyroid, and gastrointestinal cancers, as well as sarcoma and melanoma, are relatively radioresistant and are generally treated with surgery, but some data support the use of conventional radiotherapy or radiosurgery.³⁰ Expert opinion varies regarding the radiosensitivity of prostate cancer. These categorizations have become less useful as radiosurgery techniques have been introduced for the delivery of very high doses of radiation to circumscribed regions.

For patients with a short life expectancy, a single palliative radiation treatment at a dose of 8 Gy is typical.³¹ Extended treatment and higher fractionated doses are used if longer survival is anticipated. A retrospective review of five typical radiotherapy regimens showed that they were equivalent and that total doses of 30 to 40 Gy in 10 fractions provided durable tumor control.³² Radiation can be given at previously treated sites if the prior dose was moderate, the cumulative amount is limited to avoid spinal cord damage, and there is an interval of 6 months between courses.³³ Radiosurgery, the delivery of high doses of radiation to a delimited area with imaging guidance and radiation that is contoured to the shape of the tumor during one or a few treatments, may be superior to conventional radiotherapy for spinal metastasis, including for some radioresistant tumors. However, reviews of the subject acknowledge the low level of evidence for the superiority of radiosurgery over other radiation techniques for acute cord compression³⁰ and the lack of adequate comparisons with decompressive surgery.

SURGERY

Since the aforementioned review in the *Journal*,¹⁶ techniques have been developed to resect epidural tumors circumferentially, including partial re-

removal of an infiltrated vertebral body (corpectomy), and to simultaneously stabilize the spine (see the interactive graphic). Circumferential resection of the tumor yields better results than those attained previously with posterior decompression (laminectomy), because laminectomy does not reduce the ventral tumor originating in the vertebral body and the surgery may lead to spinal instability. An influential trial comparing surgical decompression followed by radiotherapy with radiotherapy alone for radioresistant tumors at a single level showed that surgery preserved ambulation for a longer time, even in some patients who were unable to walk in the 48 hours before treatment.³⁴ Continence was retained for a longer period in the surgical group, and lower doses of glucocorticoids and opioid medication were required. There was also a small but significant prolongation of survival in the surgical group. Several subsequent studies³⁵ showed little difference between surgery and radiotherapy³⁶ or favored surgery.³⁷ An analysis of 33 reports up to 2007 (before the adoption of current radiosurgery techniques) involving study populations with heterogeneous cancers concluded that surgery resulted in higher rates of recovery from paraplegia and of conversion from bedridden to ambulatory status, as well as better pain relief, than did radiotherapy.³⁸ Surgery is also an option for the treatment of spinal tumor recurrence after radiotherapy.

Spinal instability from tumor infiltration is detected with imaging or is inferred on the basis of pain with movement or spinal deformity. Radiotherapy is not an effective treatment for spinal instability. As a guide to determining whether surgery is appropriate to correct instability, a classification has been developed (the Spinal Instability Neoplastic Score [SINS]) that is based on the location of the tumor; the presence or absence of pain relief with recumbence; lytic or blastic features; and the presence or absence of spinal deformity on imaging, bone collapse, and tumor infiltration of the posterolateral elements of the spine.³⁹ Efforts to codify treatment in a larger context have been based on neurologic status, degree of cord compression, extent of metastatic disease, responsiveness to radiotherapy, and spinal stability (the neurologic, oncologic, mechanical, and systemic [NOMS] framework).⁴⁰ A recently introduced approach of separation surgery consists of resecting a portion of the tumor

in order to create a margin surrounding the spinal cord for the application of radiosurgery.⁴¹ This technique reduces radiation damage to the spinal cord.

In summary, spinal surgery is the most rapid method for relief of acute spinal cord compression and is necessary if there is spinal instability. Radiation is usually administered after surgical decompression. If radiotherapy can be delivered expeditiously, it can be used to treat cord compression due to hematologic tumors. Patients who are not expected to survive longer than the time required for recovery from the operation (generally 2 to 3 months) are treated with palliative radiotherapy.

SPINAL EPIDURAL ABSCESS

Bacterial infection of the spinal epidural space is a treacherous condition with a high rate of delayed diagnosis.^{42,43} The myelopathy of epidural abscess may appear abruptly or remain indolent for weeks. Mechanical compression of the spinal cord occurs as a result of the mass effect of the infectious collection, but vasculitic infarction has also been implicated (Fig. 3). The thoracic spine is most often affected, and abscesses usually occupy several contiguous or noncontiguous levels of the spine.

As previously summarized in the *Journal*,⁴⁴ fever and severe back pain are the main features of spinal epidural abscess, often with additional radicular pain. Bacterial infection at a site distant from the spine is found in only half of affected patients, and one fourth have no primary infection, even at autopsy. Diabetes, in particular, but also cancer, immunosuppression, renal failure, and intravenous drug and alcohol abuse are underlying conditions. In an unknown proportion of cases, the epidural infection begins as vertebral osteomyelitis. Epidural infections that arise after spinal surgery have clinical, bacteriologic, and imaging characteristics that differ from those of spontaneous infections.

ASSESSMENT

MRI, performed with the administration of gadolinium, reveals epidural abscesses, but small infections may be difficult to detect (Fig. 3B). Table 3 summarizes the imaging features of abscess and allows a comparison with the features of cord compression by tumor.⁴⁵ A distinc-

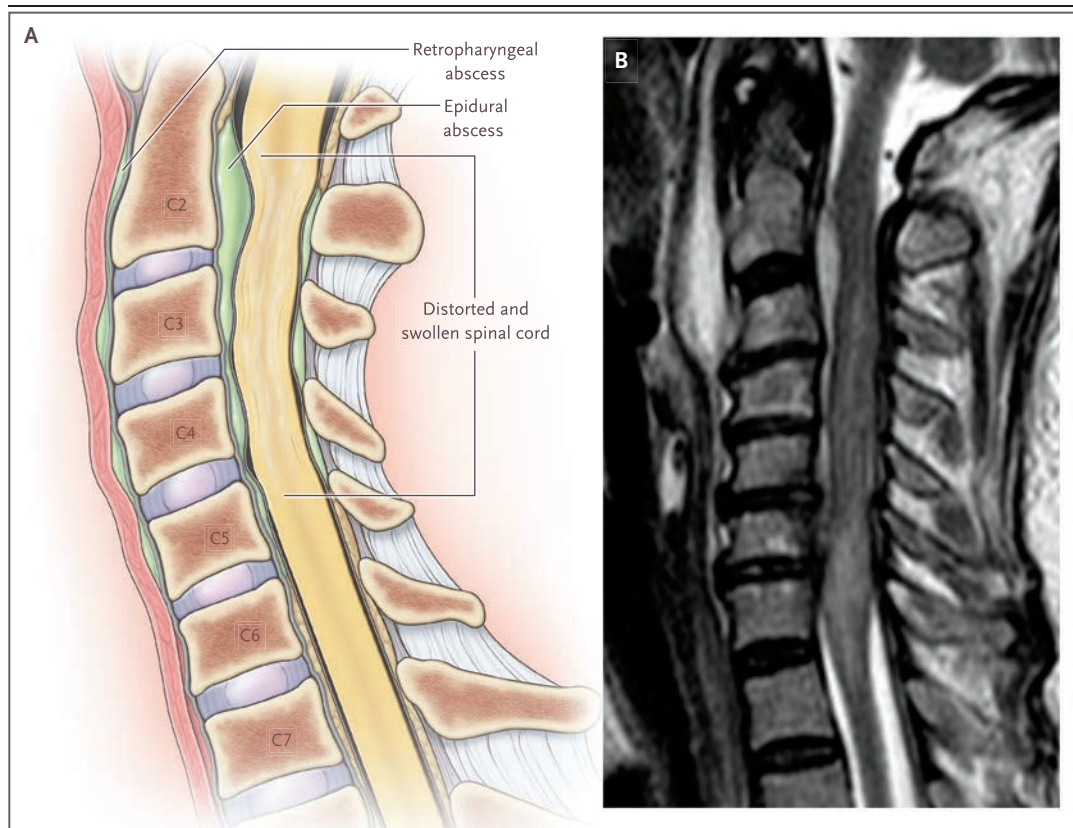


Figure 3. Acute Cervical Cord Compression Due to Epidural Abscess.

A sagittal view of the epidural abscess (Panel A) shows swelling and deformity of the cord due to the epidural pyogenic collection. A sagittal T₂-weighted MRI (Panel B) shows that the abscess is ventral to the upper cervical and mid-cervical segments and is causing compression, swelling, and displacement of the cord. The abscess is bright on T₂-weighted sequences. A prevertebral, retropharyngeal abscess is also shown, which may be the origin of an epidural abscess.

tion sometimes is made between acute purulent abscesses and subacute abscesses, which consist of granulomas or phlegmon and cause less cord compression.

Staphylococcus aureus, evenly distributed between methicillin-resistant and methicillin-sensitive organisms, is the most common pathogen cultured from the abscess or blood,⁴⁶ but a range of bacteria are found, including anaerobes. Culture of the spinal fluid rarely provides a bacteriologic diagnosis, and lumbar puncture should be avoided because of the risk of entering the infected space and contaminating the spinal fluid. Systemic leukocytosis is usually present, with elevations of the sedimentation rate and C-reactive protein level, as summarized in a meta-analysis of 915 patients.⁴⁷

TREATMENT

In uncontrolled case series, surgical evacuation of the infection has been more successful than antibiotic treatment alone.^{46,47} Decompression by means of laminectomy is most effective if it is performed before severe weakness occurs; paralysis for up to 48 hours is a poor prognostic sign but may not preclude recovery of some motor function. Surgery may also be performed to obtain infected material (to establish the causative organism) or to treat intractable pain. In the case of a longitudinally extensive abscess, it is not practical to perform laminectomies throughout the entire spine; instead, decompression is carried out at the site of the maximal infectious collection, with irrigation above and below that level. Treatment with antibiotics alone may be

adequate for an abscess that is not causing weakness; however, surgery is often required later because of progressive neurologic deficits, persistent pain, fever, and leukocytosis. Antibiotics are chosen on the basis of the identified or presumed pathogens, but there is little guidance regarding the duration or type of agent beyond the usual inclusion of drugs against methicillin-resistant staphylococcus.

SPINAL EPIDURAL HEMATOMA

The features of epidural hematoma are similar to those of the other diseases discussed here. The main features are severe back and radicular pain, followed by paraparesis or tetraparesis. Some epidural bleeding is common in traumatic spinal injury, but bleeding occurs spontaneously with the use of anticoagulant or antiplatelet medications and in patients with intrinsic coagulopathies. The MRI findings depend on the age of the hematoma (Table 3). Surgical evacuation of the clot is usually necessary if there is cord compression.^{48,49}

REFERENCES

1. Armour D. Lettsomian Lecture on the surgery of the spinal cord and its membranes. *Lancet* 1927;1:423-30.
2. Theodore N, Hadley MN, Aarabi B, et al. Prehospital cervical spinal immobilization after trauma. *Neurosurgery* 2013;72:Suppl 2:22-34.
3. Holdsworth F. Fractures, dislocations, and fracture-dislocations of the spine. *J Bone Joint Surg Am* 1970;52:1534-51.
4. Kirshblum SC, Burns SP, Biering-Sorensen F, et al. International standards for neurological and functional classification of spinal cord injury (revised 2011). *J Spinal Cord Med* 2011;34:535-46.
5. Hoffman JR, Mower WR, Wolfson AB, Todd KH, Zucker MI. Validity of a set of clinical criteria to rule out injury to the cervical spine in patients with blunt trauma. *N Engl J Med* 2000;343:94-9.
6. Stiell IG, Wells GA, Vandemheen KL, et al. The Canadian C-spine rule for radiography in alert and stable trauma patients. *JAMA* 2001;286:1841-8.
7. Ryken TC, Hadley MN, Walters BC, et al. Radiographic assessment. *Neurosurgery* 2013;72:Suppl 2:54-72.
8. Hadley MN, Walters BC. Introduction to the guidelines for the management of acute cervical spine and spinal cord injuries. *Neurosurgery* 2013;72:Suppl 2:5-16.
9. Bracken MB, Shepard MJ, Collins WF, et al. A randomized, controlled trial of methylprednisolone or naloxone in the treatment of acute spinal-cord injury: results of the second National Acute Spinal Cord Injury Study. *N Engl J Med* 1990;322:1405-11.
10. Bracken MB, Shepard MJ, Holford TR, et al. Administration of methylprednisolone for 24 or 48 hours or tirilazad mesylate for 48 hours in the treatment of acute spinal cord injury: results of the Third National Acute Spinal Cord Injury Randomized Controlled Trial: National Acute Spinal Cord Injury Study. *JAMA* 1997;277:1597-604.
11. Sayer FT, Kronvall E, Nilsson OG. Methylprednisolone treatment in acute spinal cord injury: the myth challenged through a structured analysis of published literature. *Spine J* 2006;6:335-43.
12. Hurlbert RJ, Hadley MN, Walters BC, et al. Pharmacological therapy for acute spinal cord injury. *Neurosurgery* 2013;72:Suppl 2:93-105.
13. Ryken TC, Hurlbert RJ, Hadley MN, et al. The acute cardiopulmonary management of patients with cervical spinal cord injuries. *Neurosurgery* 2013;72:Suppl 2:84-92.
14. Fehlings MG, Vaccaro A, Wilson JR, et al. Early versus delayed decompression for traumatic cervical spinal cord injury: results of the Surgical Timing in Acute Spinal Cord Injury Study (STASCIS). *PLoS One* 2012;7(2):e32037.
15. Gelb DE, Hadley MN, Aarabi B, et al. Initial closed reduction of cervical spinal fracture-dislocation injuries. *Neurosurgery* 2013;72:Suppl 2:73-83.
16. Byrne TN. Spinal cord compression from epidural metastases. *N Engl J Med* 1992;327:614-9.
17. Schiff D, O'Neill BP, Suman VJ. Spinal epidural metastasis as the initial manifestation of malignancy: clinical features and diagnostic approach. *Neurology* 1997;49:452-6.
18. Lewis DW, Packer RJ, Raney B, Rak IW, Belasco J, Lange B. Incidence, presentation, and outcome of spinal cord disease in children with systemic cancer. *Pediatrics* 1986;78:438-43.
19. Bach F, Larsen BH, Rohde K, et al. Metastatic spinal cord compression: occurrence, symptoms, clinical presentations and prognosis in 398 patients with spinal cord compression. *Acta Neurochir (Wien)* 1990;107:37-43.
20. Stark RJ, Henson RA, Evans SJ. Spinal metastases: a retrospective survey from a general hospital. *Brain* 1982;105:189-213.
21. Cook AM, Lau TN, Tomlinson MJ, Vaidya M, Wakeley CJ, Goddard P. Magnetic resonance imaging of the whole spine in suspected malignant spinal cord compression: impact on management. *Clin Oncol (R Coll Radiol)* 1998;10:39-43.
22. van der Sande JJ, Kröger R, Boogerd W. Multiple spinal epidural metastases: an unexpectedly frequent finding. *J Neurol Neurosurg Psychiatry* 1990;53:1001-3.
23. Rades D, Fehlauer F, Schulte R, et al. Prognostic factors for local control and survival after radiotherapy of metastatic spinal cord compression. *J Clin Oncol* 2006;24:3388-93.

CONCLUSIONS

The causes of acute compression of the spinal cord are distinctive but share many features, including the associated neurologic syndromes and the tendency to involve multiple levels of the spine. For many circumstances of acute cord compression, surgery is required to decompress the spinal cord and stabilize the spinal column. The disorders that account for acute spinal cord compression require an understanding of the relationship between the spinal column and the spinal cord and involve treatments that are markedly different from the ones used for common intrinsic diseases of the cord.

Dr. Alexander Ropper reports receiving travel support from DePuy Synthes, Medtronic, NuVasive, SI-BONE, and Stryker. No other potential conflict of interest relevant to this article was reported.

Disclosure forms provided by the authors are available with the full text of this article at NEJM.org.

We thank Dr. Mitchell Harris at Brigham and Women's Hospital, Dr. Ganesh Rao at M.D. Anderson Cancer Center, and Dr. Daphne Haas-Kogan at Dana-Farber Cancer Institute for advice in preparing an earlier version of the manuscript, and Dr. Michael Groff at Brigham and Women's Hospital for advice in preparing the interactive graphic.

24. Sioutos PJ, Arbit E, Meshulam CF, Galicich JH. Spinal metastases from solid tumors: analysis of factors affecting survival. *Cancer* 1995;76:1453-9.
25. Li KC, Poon PY. Sensitivity and specificity of MRI in detecting malignant spinal cord compression and in distinguishing malignant from benign compression fractures of vertebrae. *Magn Reson Imaging* 1988;6:547-56.
26. Switlyk MD, Hole KH, Skjeldal S, et al. MRI and neurological findings in patients with spinal metastases. *Acta Radiol* 2012; 53:1164-72.
27. Maranzano E, Latini P. Effectiveness of radiation therapy without surgery in metastatic spinal cord compression: final results from a prospective trial. *Int J Radiat Oncol Biol Phys* 1995;32:959-67.
28. Graham PH, Capp A, Delaney G, et al. A pilot randomised comparison of dexamethasone 96 mg vs 16 mg per day for malignant spinal-cord compression treated by radiotherapy: TROG 01.05 Superdex study. *Clin Oncol (R Coll Radiol)* 2006;18:70-6.
29. Vecht CJ, Haaxma-Reiche H, van Putten WL, de Visser M, Vries EP, Twijnstra A. Initial bolus of conventional versus high-dose dexamethasone in metastatic spinal cord compression. *Neurology* 1989;39: 1255-7.
30. Gerszten PC, Mendel E, Yamada Y. Radiotherapy and radiosurgery for metastatic spine disease: what are the options, indications, and outcomes? *Spine (Phila Pa 1976)* 2009;34:Suppl:S78-92.
31. Maranzano E, Bellavita R, Rossi R, et al. Short-course versus split-course radiotherapy in metastatic spinal cord compression: results of a phase III, randomized, multicenter trial. *J Clin Oncol* 2005;23:3358-65.
32. Rades D, Stalpers LJ, Veninga T, et al. Evaluation of five radiation schedules and prognostic factors for metastatic spinal cord compression. *J Clin Oncol* 2005;23: 3366-75.
33. Nieder C, Grosu AL, Andratschke NH, Molls M. Update of human spinal cord re-irradiation tolerance based on additional data from 38 patients. *Int J Radiat Oncol Biol Phys* 2006;66:1446-9.
34. Patchell RA, Tibbs PA, Regine WF, et al. Direct decompressive surgical resection in the treatment of spinal cord compression caused by metastatic cancer: a randomised trial. *Lancet* 2005;366:643-8.
35. Loblaw DA, Mitera G, Ford M, Laperriere NJ. A 2011 updated systematic review and clinical practice guideline for the management of malignant extradural spinal cord compression. *Int J Radiat Oncol Biol Phys* 2012;84:312-7.
36. Rades D, Huttenlocher S, Dunst J, et al. Matched pair analysis comparing surgery followed by radiotherapy and radiotherapy alone for metastatic spinal cord compression. *J Clin Oncol* 2010;28:3597-604.
37. Klimo P Jr, Thompson CJ, Kestle JR, Schmidt MH. A meta-analysis of surgery versus conventional radiotherapy for the treatment of metastatic spinal epidural disease. *Neuro Oncol* 2005;7:64-76.
38. Kim SD, Melikian R, Ju KL, et al. Independent predictors of failure of nonoperative management of spinal epidural abscesses. *Spine J* 2014;14:1673-9.
39. Fisher CG, DiPaola CP, Ryken TC, et al. A novel classification system for spinal instability in neoplastic disease: an evidence-based approach and expert consensus from the Spine Oncology Study Group. *Spine (Phila Pa 1976)* 2010;35(22):E1221-9.
40. Laufer I, Rubin DG, Lis E, et al. The NOMS framework: approach to the treatment of spinal metastatic tumors. *Oncologist* 2013;18:744-51.
41. Bate BG, Khan NR, Kimball BY, Gabrick K, Weaver J. Stereotactic radiosurgery for spinal metastases with or without separation surgery. *J Neurosurg Spine* 2015;22:409-15.
42. Davis DP, Wold RM, Patel RJ, et al. The clinical presentation and impact of diagnostic delays on emergency department patients with spinal epidural abscess. *J Emerg Med* 2004;26:285-91.
43. Baker AS, Ojemann RG, Swartz MN, Richardson EP Jr. Spinal epidural abscess. *N Engl J Med* 1975;293:463-8.
44. Darouiche RO. Spinal epidural abscess. *N Engl J Med* 2006;355:2012-20.
45. Avilucea FR, Patel AA. Epidural infection: is it really an abscess? *Surg Neurol Int* 2012;3:Suppl 5:S370-6.
46. Patel AR, Alton TB, Bransford RJ, Lee MJ, Bellabarba CB, Chapman JR. Spinal epidural abscesses: risk factors, medical versus surgical management, a retrospective review of 128 cases. *Spine J* 2014;14: 326-30.
47. Reihnsaus E, Waldbaur H, Seeling W. Spinal epidural abscess: a meta-analysis of 915 patients. *Neurosurg Rev* 2000;23: 175-205.
48. Shin JJ, Kuh SU, Cho YE. Surgical management of spontaneous spinal epidural hematoma. *Eur Spine J* 2006;15:998-1004.
49. Zhong W, Chen H, You C, Li J, Liu Y, Huang S. Spontaneous spinal epidural hematoma. *J Clin Neurosci* 2011;18:1490-4.

Copyright © 2017 Massachusetts Medical Society.

IMAGES IN CLINICAL MEDICINE

The *Journal* welcomes consideration of new submissions for Images in Clinical Medicine. Instructions for authors and procedures for submissions can be found on the *Journal's* website at NEJM.org. At the discretion of the editor, images that are accepted for publication may appear in the print version of the *Journal*, the electronic version, or both.